





Clinicoepidemiological Findings and Pathological Characteristics of Different Types of Cutaneous Warts

Hawkar Ibrahim Abdullah ^{a *} , Ali Hussein Hassan ^b 

^a Medical Laboratory Department, College of Health & Medical Technology, Sulaimani Polytechnic University, Sulaymaniyah, Iraq.

^b Department of Basic Sciences, College of Dentistry, University of Sulaimani, Sulaymaniyah, Iraq.

Submitted: 26 April 2025

Revised: 31 May 2025

Accepted: 5 June 2025

* **Corresponding Author:**
hawkar.abdullah.chmt@spu.edu.iq

Keywords: Skin diseases, HPV infection, Common warts, Genital warts, Koilocytosis.

How to cite this paper: H.I. Abdullah, A. H. Hassan "Cutaneous Warts in Sulaymaniyah Governorate in Iraq Kurdistan Region. Clinical, Epidemiological, and Pathological Study", KJAR, vol. 10, no. 1, pp: 158-169, June 2025, doi: [10.24017/science.2025.1.10](https://doi.org/10.24017/science.2025.1.10)



Copyright: © 2025 by the authors. This article is an open access article distributed under the terms and conditions of the Creative Commons Attribution (CC BY-NC-ND 4.0)

Abstract: Cutaneous warts, which result from infections by human papillomaviruses, are a common skin disease worldwide. They are categorized as common, plantar, plane, genital, filiform, periungual and mosaic warts. Genital warts represent the most common sexually transmitted infections; however, no sufficient information are available in Iraqi Kurdistan region, concerning their frequency rates; therefore, this study aims to determine the epidemiological and clinical features of patients with warts in this region, with special emphasis on estimating the frequency rates of genital warts and on analyzing their histopathological characteristics. A specially designed questionnaire was designed to collect socio-demographic and clinical data, such as age, gender, occupation, education and residency, from 420 patients with wart, together with the type and anatomical location of the warts. In addition, histopathological examination was performed for 20 patients with genital warts. Out of the total number of wart patients involved in this study, 255 were males, and 165 were females. Common warts were the most common type (39.0%) followed by the plantar and genital warts (30.5% and 11.9% respectively). Students were the most common individuals affected by the warts (46.0%), followed by self-employed persons (29.5%). Among patients with genital warts, most of the wart lesions were seen in multiple locations around the genital organs, and the papular form was the most frequent type seen. Histopathological examination of the genital wart lesions showed papillomatosis, acanthosis, koilocytosis, dysplasia, parakeratosis, and one case of squamous cell carcinoma *in situ*.

1. Introduction

Cutaneous warts are the third most common skin disorder worldwide [1]. They are induced by infection with Human papillomavirus (HPV), is a double-stranded circular DNA virus belonging to the papillomavirus family [2]. It primarily infects the basal keratinocytes, resulting in irregular cellular proliferation in the cutaneous and mucosal tissues [3-7]. Skin warts appear as one or more keratotic papules of variable size and shape on exposed regions of the body, including the genital area, as well as the hands, feet, and face, based on the HPV subtype and they are categorized as common warts, plantar warts, plane warts, genital warts, filiform warts, periungual warts and mosaic warts [8-12]. There are about 40 types of HPVs known to infect humans, and they are classified into high-risk (HR-HPVs) and low-risk (LR-HPVs) according to their carcinogenic potential [13, 14]. The high-risk HPVs include at least 12 types, but only two of them (types 16 and 18) cause the majority of HPV-related cancers, including those involving the cervix, vagina, vulva, penis, and anus [15-17].

High-grade dysplasia and even invasive malignant squamous cell carcinoma of infected skin and mucosal surfaces, including oropharyngeal and anogenital cancers, can be caused by the HR-HPVs, whereas the LR-HPVs are mainly responsible for benign epithelial proliferations such as condylomas, and they may also contribute to some subtypes of non-cervical malignant tumors [18, 19].

Genital warts (GWs), also known as *Condylomata Acuminata*, represent the most common sexually transmitted infections, and their incidence is constantly growing among sexually active people, especially young adults [20-22]. They come in four primary morphological varieties: keratotic, flat, papule, and massive *Condylomata*, which occur as visible lesions in the vulva, perineum, anus, vagina, cervix, urethra, scrotum, and penile region [23-25]. Given this diagnosis complexity, the Centers for Disease Control and Prevention guidelines suggest testing individuals with GWs for other sexually transmitted diseases, including hepatitis B virus (HBV), hepatitis C virus (HCV), human immunodeficiency virus (HIV) and venereal disease research laboratory (VDRL) [26, 27].

Genital warts are frequently asymptomatic but affect patients psychologically and reduce the quality of their lives. They also represent a significant public health problem worldwide, especially in developing countries [28-30]. Their worldwide annual incidence is from 160 to 289 per 100,000, and their worldwide prevalence ranges from 5% to 20% [31].

In the Iraqi Kurdistan region, information concerning the frequency of GWs appears to be insufficient. Thus, understanding their epidemiology and clinical presentation is crucial for effective treatment. This cross-sectional study aimed to determine epidemiological and clinical features of patients with warts consulting the dermatology centre in Sulaymaniyah Governorate in Iraqi Kurdistan region from September 2024 to January 2025 with special emphasis on the frequency rates and histological characteristics of GWs.

2. Materials and Methods

2.1 Patients and Study Design

Four hundred and twenty patients with warts visiting the dermatology center in Sulaymaniyah Governorate were enrolled in this cross-sectional study from October 2024 to January 2025. This study included new confirmed wart cases of different-aged male and female patients, whereas patients attending follow-up appointments and pregnant female patients were excluded. Before enrollment, patients were given a detailed verbal explanation of the study objectives and procedures, and informed consent was obtained from every participant.

2.2. Ethics Approval and Consent to Participate

The protocol of this study was approved by Sulaymaniyah General Directorate of Health (Approval number 2159 on 17/10/2024) and by the research ethics committee of the College of Health and Medical Technology in the Sulaimani Polytechnic University (Approval number 22/245 on 01/12/2024). Informed consent was obtained from each patient involved in the present study

2.3. Patients' Questionnaire and Categorizing Types of Warts

A specially designed questionnaire covering socio-demographic and clinical data of patients who had warts was administered. Patients were personally interviewed, and the questionnaire was completed based on their responses. The type of wart in each patient was diagnosed and photographed by expert dermatologists based on clinical and morphological findings of the skin lesion as follows: common warts appeared as exophytic, hyperkeratotic, rough, raised papules; plane warts as smooth, flat-topped, light brown or skin-colored papule; plantar warts as painful, pinpoint black dots on the soles; anogenital warts as small, soft, cauliflower-like, exophytic papules; filiform warts as thread-like, elongated projections; periungual warts as rough, irregular, thickened growth around the fingernail; and mosaics warts as clusters of tightly grouped, small, flat or slightly raised warts that form a larger plaque with a mosaic pattern.

2.4. Biopsy Collection from Patients with Genital Warts

Excisional biopsies were collected under local anaesthesia by expert dermatologists from patients with GWs who are at least 18 years old, together with blood to screen for HIV, HBV, HCV, and VDRL to exclude any other sexually transmitted diseases and to prevent contamination of the material used in the procedure. After excision, the biopsies were fixed in 10% neutral buffered formalin for 24 hours. The histopathological preparation and examination were performed by an expert pathologist for confirmation of the GWs diagnosis and to identify their histopathological characteristics.

2.5. Statistical Analysis

The statistical analysis was conducted using IBM SPSS version 26 (IBM Corp, Armonk, NY, USA) and Microsoft Excel. Qualitative variables were presented as frequency and percentage. The Chi-square and Fisher exact tests were applied to compare the frequencies between groups. A p-value of < 0.05 was considered statistically significant.

3. Results

3.1.1. Demographic Characteristics of Patients

As shown in table 1, out of the 420 patients with warts involved by this study, 255 were males (60.7 %), and 165 were females (39.3 %.), with a male-to-female ratio of 1.55:1. The patient's ages ranged from 2 to 70 years, with a mean age of 24.51years. Patients between 1 and 12 years old were the most affected, and those older than 55 were the least affected patient groups in comparison with other age groups (p value < 0.05). Regarding the education level, university graduates constituted 25.5% of patients, and they comprised the most commonly affected group compared to patients' groups with other education levels (p value < 0.05). Students constituted 46% of patients, and they represent the highest frequency of patients in comparison with patients' groups of other occupations. Although non-significant, the number of patients from urban regions was larger than that of those from rural regions (p value < 0.05).

Table 1: Socio-demographic characteristics and key study variables of patients categorized by gender.

Variable	Male (N=255, 60.7%)	Female (N=165, 39.3%)	Total (N=420, 100%)	P value
Age				
1-12	70 (16.7%)	28 (6.7%)	98 (23.3%)	0.024
13-18	65 (15.5%)	31 (7.4%)	96 (22.9%)	
19-24	35 (8.3%)	23 (5.5%)	58 (13.8%)	
25-34	25 (6.0%)	28 (6.7%)	53 (12.6%)	
35-44	26 (6.2%)	24 (5.7%)	50 (11.9%)	
45-54	22 (5.2%)	18 (4.3%)	40 (9.5%)	
55-above	12 (2.9%)	13 (3.1%)	25 (6.0%)	
Residency				
Urban area	180 (42.9%)	112 (26.7%)	292 (69.5%)	0.58
Rural area	75 (17.9%)	53 (12.6%)	128 (30.5%)	
Education level				
Illiterate	52 (12.4%)	44 (10.5%)	96 (22.9%)	0.028
Primary school	87 (20.7%)	35 (8.3%)	122 (29.0%)	
High school	57 (13.6%)	37 (8.8%)	94 (22.4%)	
College/University	58 (13.8%)	49 (11.7%)	107 (25.5%)	
Postgraduate	1 (0.2%)	(0.0%)	(0.2%)	

3.1.2. Numbers and Anatomical Distribution of Wart Types Observed in the Present Study

Common wart was the most frequent type seen in this study (Figure 1, A and B), affecting 164 out of the total 420 patients (39.5%), followed by the planter wart (Figure 1, C and D), affecting 128 patients, 30.5%), GWs (50 patients, 11.9%), peri-ungual wart (27 patients, 6.4%), plane wart (15 patients, 3.6%) and filiform wart (24 patients, 5.7%). The least frequent type was mosaic wart affecting only 12 patients (2.9%). Highly significant variations (p ≤ 0.01) were seen among the number of wart cases in relation to

their types and locations (Table 2). Although statistically non-significant ($p \leq 0.5$), the numbers of different types of warts were higher in males than in female patients (Figure 2). Most of the wart lesions were seen on the hands of patients (38.81%), followed by those seen on the feet (37.6%), anogenital region (11.9%), face (10.2%), and scalp (1.4 %) (Figure 3).

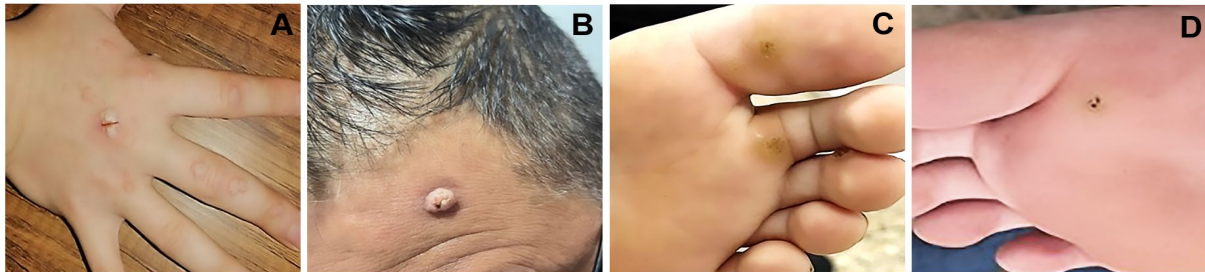


Figure 1: Gross morphology of common and planter warts seen in patients involved by the present study. **A** and **B:** Common warts. **C** and **D:** Planter warts.

Table 2: Numbers of wart patients involved in the current study in relation to type and anatomical distribution of wart lesions.

Type of wart	Hands	Feet	Genital	Face	Scalp	Total
Common warts	138 (32.9%)	11 (2.6%)	0 (0.0%)	14 (3.3%)	1 (0.2%)	164 (39.0%) ^a
Genital warts	0 (0.0%)	0 (0.0%)	50 (11.9%)	0 (0.0%)	0 (0.0%)	50 (11.9%) ^c
Planter warts	0 (0.0%)	128 (30.2%)	0 (0.0%)	0 (0.0%)	0 (0.0%)	128 (30.5%) ^b
Plane warts	3 (0.7%)	2 (0.5%)	0 (0.0%)	10 (2.4%)	0 (0.0%)	15 (3.6%) ^e
Filiform warts	0 (0.0%)	0(0.0%)	0 (0.0%)	19 (4.5%)	5 (1.2%)	24 (5.7%) ^d
Periungual warts	21 (5.0%)	6 (1.4%)	0 (0.0%)	0 (0.0%)	0 (0.0%)	27 (6.4%) ^d
Mosaic warts	1 (0.2%)	11 (2.6%)	0 (0.0%)	0 (0.0%)	0 (0.0%)	12 (2.9%) ^e
Total	163 (38.81%)	158 (37.6%)	50 (11.9%)	43 (10.2%)	6 (1.4%)	420 (100.0%)

* Within the last column, numbers of patients with different superscript small alphabetical letters are statistically different from each other ($p \leq 0.5$).

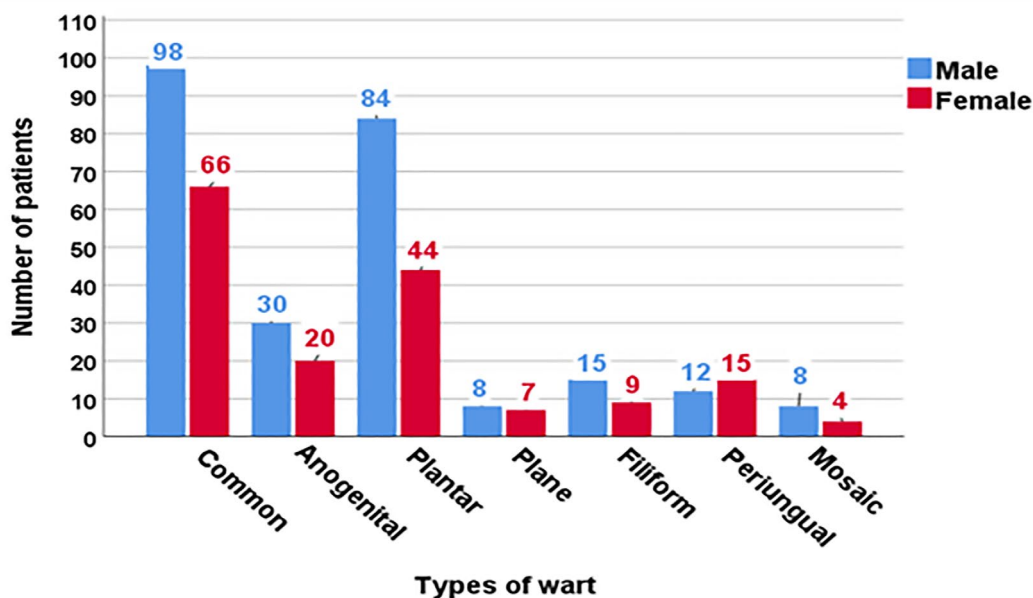


Figure 2: Types and numbers of wart cases in patients involved in the current study.

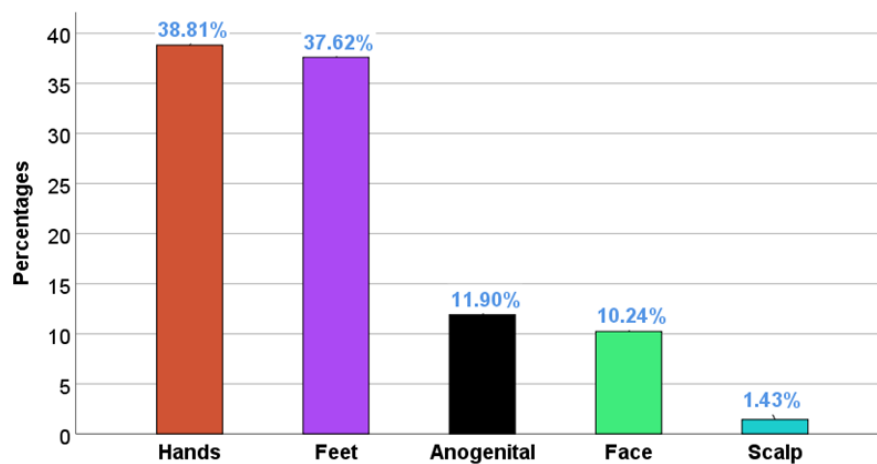


Figure 3: Anatomical location of wart lesions in patients involved by the current study.

3.1.3. Numbers and Types of Warts in Patients in Relation to their Occupation

As shown in table 3, the most numerous patients encountered in the present study were students (193 out of the total 420 patients), and their number was significantly higher ($p \leq 0.5$) than patients from other occupations. Common wart was the most frequent type affecting students (86 patients), followed by the planter wart (65 patients), filiform wart and periungual wart (14 patients each), plane wart (8 patients), mosaic wart (5 patients) and GWs (1 patient). Self-employed were the second most numerous patients (124 out of 420), and most of them were affected by the plantar wart (42 patients), followed by the common wart (36 patients) and GWs (27 patients). Employed were the third most numerous patients (50 out of 420), and they were mostly affected by the common wart (22 patients), followed by the GW (12 patients) and plantar wart (11 patients). Individuals with the unknown occupation “others” were the next numerous patients (34 out of 420) in whom the common wart was the most frequent type (14 patients), followed by GWs (8 patients) and planter wart (8 patients). The least numerous patients were the unemployed (19 out of 420), and most of them were affected by the periungual wart (8 patients), followed by the common wart (6 patients).

Table 3: Numbers of wart cases and types of warts seen in patients according to their occupation.

Occupation	Common	Anogenital	Plantar	Plane	Filiform	Periungual	Mosaic	Total
Student	86 (20.5%)	1 (0.2%)	65 (15.5%)	8 (1.9%)	14 (3.3%)	14 (3.3%)	5 (1.2%)	193 (46.0%)
Self-employed	36 (8.6%)	27 (6.4%)	42 (10.0%)	5 (1.2%)	7 (1.7%)	3 (0.7%)	4 (1.0%)	124 (29.5%)
Employed	22 (5.2%)	12 (2.9%)	11 (2.6%)	2 (0.5%)	1 (0.2%)	1 (0.2%)	1 (0.2%)	50 (11.9%)
Other	14 (3.3%)	8 (1.9%)	8 (1.9%)	0 (0.0%)	1 (0.2%)	1 (0.2%)	2 (0.5%)	34 (8.1%)
Unemployed	6 (1.4%)	2 (0.5%)	2 (0.5%)	0 (0.0%)	1 (0.2%)	8 (1.9%)	0 (0.0%)	19 (4.5%)
Total	164 (39.0%)	50 (11.9%)	128 (30.5%)	15 (3.6%)	24 (5.7%)	27 (6.4%)	12 (2.9%)	420 (100.0%)

3.2. Sexually Transmitted Diseases Screening

Genital warts cases were seen in 30 male and 20 female patients out of the total 420 patients with warts involved in the present study. With the exception of a VDRL-positive test in only one male patient, all other patients were negative for the sexually transmitted diseases screening (Table 4).

Table 4: Sexually transmitted diseases screening test results.

Gender	HIV Positive	HCV Positive	HBsAg Positive	VDRL Positive	STD Negative
Male	0 (0%)	0 (0%)	0 (0%)	1 (3.3%)	29 (58%)
Female	0 (0%)	0 (0%)	0 (0%)	0 (0%)	20 (60%)
Total	0 (0%)	0 (0%)	0 (0%)	1 (2%)	49 (98%)

HIV: Human Immunodeficiency Virus, HCV: Hepatitis C virus, HBsAg: hepatitis B surface antigen, VDRL: Venereal Disease Research Laboratory test.

3.3. Morphological Characteristics of Genital Wart Lesions and Age Distribution

3.3.1. Age Distribution of Genital Wart Patients

Regarding the GW patients, the age distribution was as follows, only five patients were recorded in the age group of 1-2 years, and there were no patients recorded in the age group of 13-18 years. In the age group of 19-24 years, there were five patients, while the age group of 25-34 years had the highest number, 17 patients. Additionally, 15 patients were documented in the age group of 35-44 years, seven patients in the age group of 45-54 years, and one patient was recorded in the age group above 55 years as shown in figure 4.

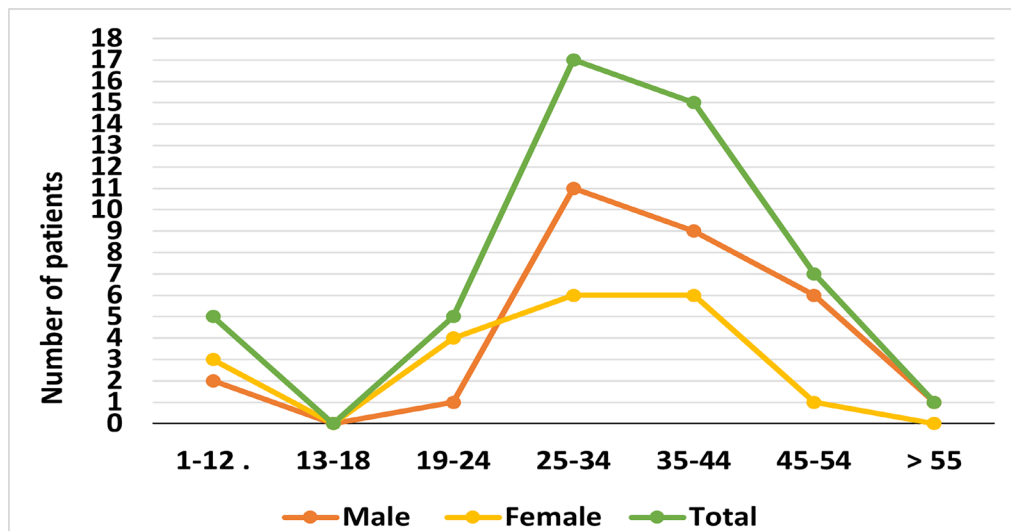


Figure 4: Distribution of genital warts cases across different age groups.

3.3.2. Gross Morphological Characteristics of Genital Warts

Genital wart lesions encountered in the present study include the papular form, which was seen in 28 out of the total 50 patients with GW (56%), the Cauliflower-like form in 15 patients (30%), and the flat form in seven patients (14%) (Table 5 and Figure 5). As shown in figure 6, the GW lesions were seen in multiple locations throughout the male or female external genitalia in 19 out of the total 50 GW patients (38%), on the penile shaft in 14 patients (28%), suprapubic region in eight patients (16%), vulva in three patients (6%), inguinal in two patients (4%), scrotum two patients (4%), and perianal region two patients (4%).

Table 5: Different gross morphological types of genital warts, their numbers and percentage in the current study.

Type of genital wart	Numbers and percentages of patients
Papular	28 (56%)
Cauliflower-like	15 (30%)
Flat	7 (14%)
Total	50 (100%)

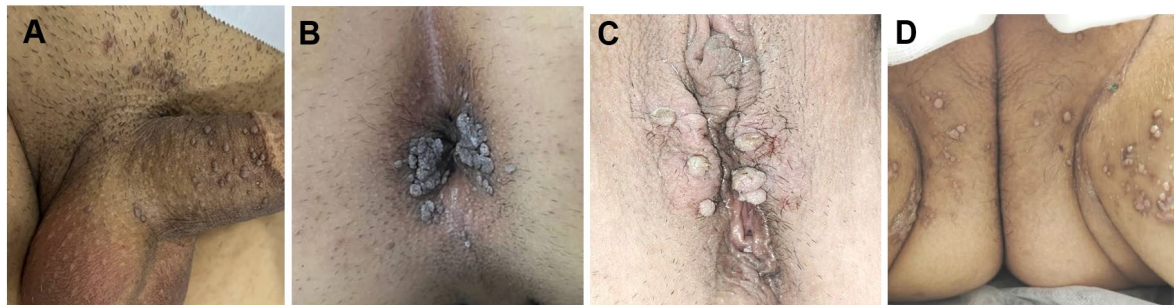


Figure 5: Gross morphology of genital warts seen in patients involved by the present study. **A:** Papular warts on the penile shaft, scrotum, and supra-pubic area in a 27-year-old male patient. **B:** Cauliflower-like perianal warts in a 35-year-old male patient. **C:** Cauliflower-like vulval warts in a 37-year-old female. **D:** Papular warts on the perianal, inguinal, and vulva of a 12-year-old female patient.

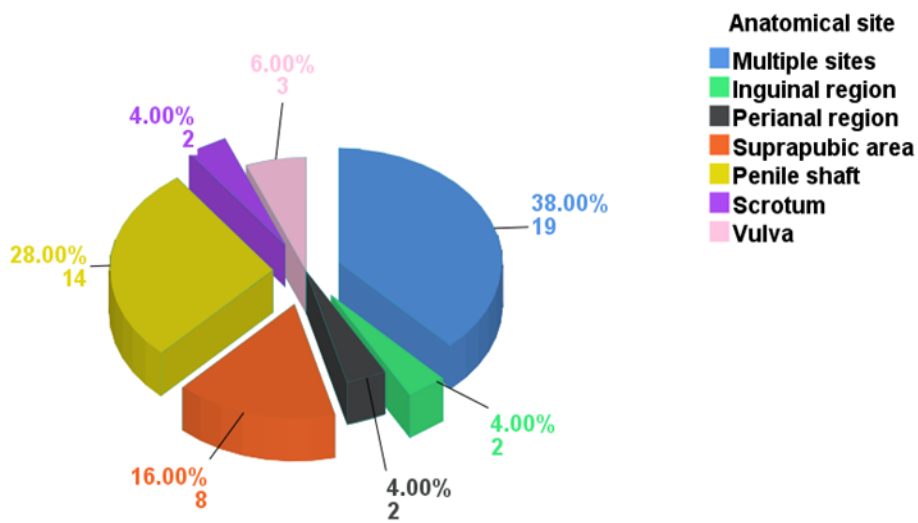


Figure 6: Anatomical distribution of genital warts among male and female patients.

3.3.3. Microscopic Morphological Characteristics

The microscopic morphological characteristics were examined in 20 (11 males and 9 females) out of the total 50 patients with GWs encountered in the present study. parakeratosis in 11 males (55%) and six females (30%), acanthosis in 11 males (55%) and nine females (45%), koilocytosis in nine males (45%) and eight females (40%), papillomatosis in two males (10%) and one female (5%), and dysplasia in two males (10%) and one female (5%) (Figure 7). Squamous cell carcinoma in situ was seen in one case on the suprapubic region of a 40-year-old male patient. It was characterized by loss of maturation and disorganization that involves more than two thirds of the full epithelial thickness associated with cellular and nuclear pleomorphism and increased mitotic activity, including some atypical figures. In addition, it was associated with acanthosis, parakeratosis, hyperkeratosis, downward extended keratin-encircling epithelial buddings and koilocytosis, which was seen in scattered epidermal cells (Figure 8).

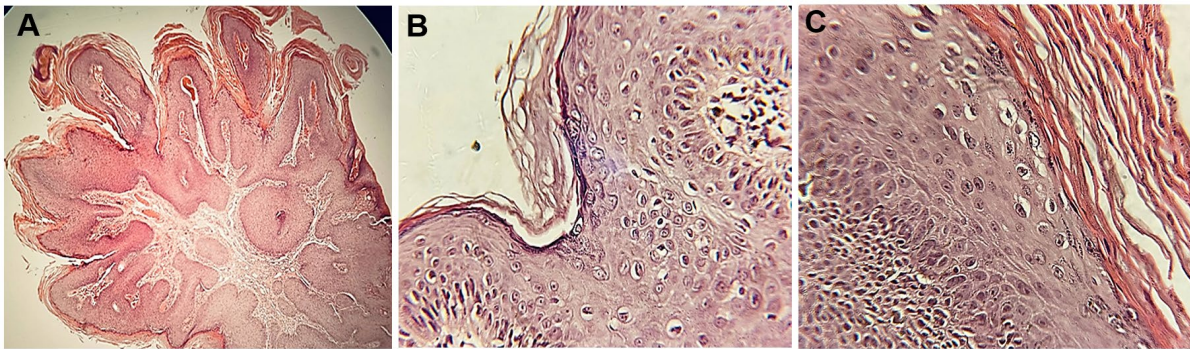


Figure 7: Microscopic morphology of genital warts seen in patients involved by the present study. **A:** Papillomatosis, hyperkeratosis and acanthosis, **B:** Focal hyperkeratosis and koilocytosis in scattered epidermal cells. **C:** Hyperkeratosis, parakeratosis and koilocytosis in scattered cells. H&E, A X100, B&C X400.

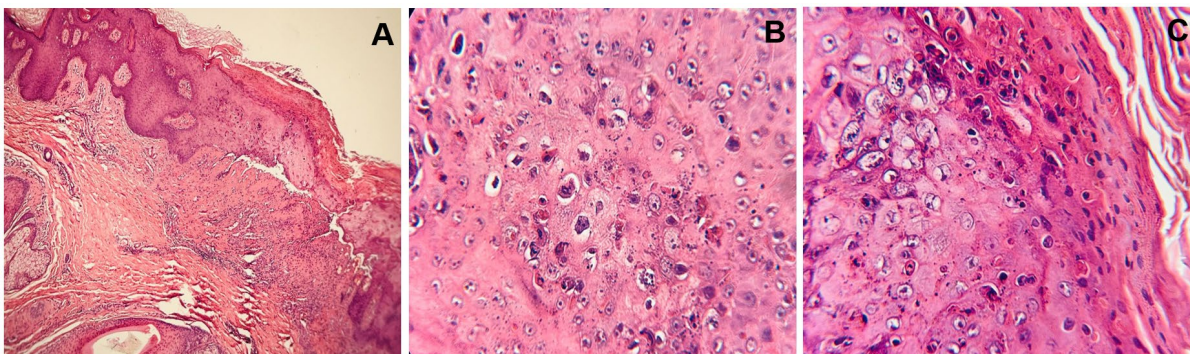


Figure 8: Microscopic morphology of a genital wart lesion excised from the suprapubic region of a 40-year-old male patient showing squamous cell carcinoma in situ. **A:** Acanthosis and focal hyperkeratosis **B** and **C:** Loss of maturation as evident by the disorganization that involves more than two thirds of the full epithelial thickness associated with cellular and nuclear pleomorphism and increased mitotic activity, including some atypical figures. Koilocytosis are seen in scattered epidermal cells. H&E, A X100, B&C X400.

4. Discussion

Out of the 420 patients involved in this study, 255 were male, and 165 were female. This finding, which reveals that males are more likely to be affected by warts than females, is in agreement with Ghadgepatil *et al.* [1] and Gönül *et al.* [32] who encountered similar findings among patients with warts in India and Turkey; however, it disagrees with Qi *et al.* [33] who reported that wart affects females more than males in China. This variability can be attributed to the fact that males are more likely to be exposed to outdoor activities than females in our society. Patients of the 1–18-year-old years were mostly affected in comparison with older ages. This finding, which is approximately consistent with comparable studies achieved in India and Pakistan [1, 34], can be ascribed to the non-fully developed immune system in children and adolescents and the greater likelihood of contact with HPV-infected patients because of their engagement in sports and other outdoor physical activities.

Patients living in urban areas represent 69.5% of patients involved by the present study compared to 30.5% living in rural areas. This finding, which is in agreement with [35, 36], can be attributed to the highest population found in cities and to the availability of specialized skin diseases departments and centers in the urban areas where the numbers and frequencies of different skin diseases are constant.

Most patients with cutaneous warts involved by the present study had a primary school education level (29%), followed by university graduates (25.5%), illiterates (22.9%), high school (22.4%) and post-graduates (0.2%). This finding, which indicates that the level of educations has no effect on the frequency rates of warts among patients involved by the present study, reflects the lack of essential disease prophylaxis and control information in the teaching curriculum in the different education levels in our developing country where the hygiene levels are poor and the risk of exposure to the HPVs is high

especially among people living in crowded settings [37, 38]. However, this finding is not in agreement with the study of Muhammad and Sherwany, which revealed that the majority of GW patients were illiterates [23]. This disagreement can be attributed to the diversity of the present study, which involves all types of warts, whereas the Erbil study focused on GWs.

Most wart lesions were seen on the hand (38.8%) and feet (37.62%), followed by those seen on the anogenital region (11.0 %), face (10.24%), and scalp (1.43%). This finding, which is in agreement with findings of other studies achieved in India [1], Pakistan [34], Egypt [39], Nepal [40] and Turkey [32], indicates that hands and feet as body parts mostly affected by the wart because they are readily accessible to the contact with wart patients and contaminated surfaces during work, play, or any other outdoor activities. The high percentage of GW cases seen in this study (11.9%), which is consistent with the study of [41] in Kuwait, may be attributed to the higher sexual activity of affected patients and the lack of vaccination. In addition, some of the GW patients seen in this study were coming to the skin diseases center in Sulaymaniyah from other Iraqi cities to obtain treatment and to avoid any embarrassment or stigma that may arise if they became recognized by their friends and relatives in their own cities.

Most of the patients involved in this study were students (46%), followed by the self-employed (29.5%), employees (11.9%), others with unspecified occupation (8.1%), and the unemployed (4.5%). The finding, which is in agreement with comparable studies achieved in India [9] and Nepal [40], can be ascribed to the high opportunity of contact of the students, self-employed individuals, and employed individuals with wart patients in schools, universities, and workplaces and it also can be attributed to the high level of outdoor activities performed by such individuals which may damage the epidermal barrier and create an entry point for the HPVs.

Genital wart lesions were encountered with a considerable frequency in 1–12-year-old children (5 out of the total 50 patients with GW) encountered in the current study. This finding is consistent with a comparable study achieved in Kuwait [41]; however, it is inconsistent with another study achieved in Egypt [39] which revealed less frequent cases of GW among children. Children may become affected by the GW through perinatal transmission of the HPVs from their mothers or through sexual assault [42]. In contrast, no GW cases were seen in the 13-18 year old patients involved in this study. This finding is most probably not representative of the accurate situation, and it may be attributed to the shameful feelings of adolescents and the young with GWs; therefore, they prefer not to tell anyone, including dermatologists, about their genital skin lesions to avoid social stigma and embarrassment.

Most of the GWs seen in females involved in the present study were encountered in multiple locations around the external genitalia, including the vulva, vagina, supra pubic, inguinal, and perianal region, whereas in males, most of them were encountered on the penile shaft. This finding, which is consistent with comparable studies achieved in Erbil city of Iraq [22, 40], indicates that these body parts are particularly susceptible to HPV transmission during sexual intercourse.

Gross morphology of GW lesions encountered in the present study includes papular, cauliflower, and flat. This finding is in agreement with the general concept that GWs vary from small, flat-topped papules to large, cauliflower-like lesions on the anogenital mucosa and surrounding skin [43]. On the other hand, the microscopic morphology includes acanthosis, papillomatosis, hyperkeratosis, parakeratosis, dysplasia, and koilocytosis. These pathological changes develop due to the invasion of the basal epidermal cell layer by the HPV, resulting in disruption of the cellular homeostasis and intense proliferation of the epidermal cells [44, 45]. The occurrence of koilocytes, "large atypical keratinocytes with eccentric, pyknotic nuclei surrounded by a perinuclear halo," is considered a hallmark of an HPV-infected cell [46, 47]. In addition, squamous cell carcinoma in situ has been identified in an excisional biopsy obtained from the suprapubic region of a male patient with GW involved by the present study. This finding confirms the perception that patients with GW have an increased risk of HPV-related cancers, especially anogenital malignancies [48].

The study has some limitations such as many patients with warts do not know about the skin disease centers available in this region and directly visit the private skin disease clinics or patients know the skin disease center, but they prefer to visit private skin disease clinics. Further, more patients with GWs are present in this region, but they were not included in the present study as they prefer not to

visit the skin disease center to avoid embarrassment and stigma. Lastly, the refusal of biopsy collection by many patients with GWs as they were worried about the anesthesia, pain, and possible bleeding.

5. Conclusions

Warts represent a prevalent infection affecting both the skin and mucous membranes and carry the risk of contagion, particularly among young male and female students. This study has shown that students emerged as the predominant patient group, with common warts being the most frequently observed variant followed by plantar warts and GWs. The histopathological analysis confirmed that the majority of cases were benign. However, one case of squamous cell carcinoma in situ was seen, underscoring the critical role of histopathological examination in the assessment and management of wart-related conditions.

Acknowledgment: The authors would like to extend their thanks and deep appreciation to the directorate and staff of the Skin Disease Center in Sulaymaniyah city for their help and support in obtaining data and collection of the study samples Also, and also special thanks to Dr. Hasanen Hafidh Khudair for his assistance in reviewing and interpreting the histopathological slides.

Author contributions: **Hawkar Ibrahim Abdullah:** Conceptualization, writing review & editing, methodology, data curation, investigation, formal analysis and writing original draft, **Ali Hussein Hassan:** Conceptualization, methodology, formal analysis and validation.

Data availability: Data will be available upon reasonable request.

Conflicts of interest: The authors declare that they have no known competing financial interests or personal relationships that could have appeared to influence the work reported in this paper.

Funding: The authors did not receive support from any organization for the submitted work.

References

- [1] S. S. Ghadgepatil, S. Gupta, and Y. K. Sharma, "Clinicoepidemiological study of different types of warts," *Dermatology research and practice*, vol. 2016, no. 1, pp. 1–4, Jan. 2016, doi: <https://doi.org/10.1155/2016/7989817>.
- [2] S. Gupta, P. Kumar, and B. C. Das, "HPV: Molecular pathways and targets," *Current problems in cancer*, vol. 42, no. 2, pp. 161-174, March–April 2018, doi: <https://doi.org/10.1016/j.currprobcancer.2018.03.003>.
- [3] A. Herzum *et al.*, "Treatment of pediatric anogenital warts in the era of HPV-vaccine: a literature review," *Journal of Clinical Medicine*, vol. 12, no. 13, p. 4230, Dec. 2023, doi: <https://doi.org/10.3390/jcm12134230>.
- [4] L. Skubic, V. Breznik, and M. Poljak, "Different skin wart types, different human papillomavirus types? A narrative review," *Acta Dermatovenerologica Alpina, Panonica et Adriatica*, vol. 32, no. 4, pp. 165-171, Dec. 2023, doi: <https://doi.org/10.15570/actaapa.2023.30>.
- [5] P. Zhu *et al.*, "Clinical guideline for the diagnosis and treatment of cutaneous warts (2022)," *Journal of Evidence-Based Medicine*, vol. 15, no. 3, pp. 284-301, September 2022, doi: <https://doi.org/10.1111/jebm.12494>.
- [6] C. S. Ahn and W. W. Huang, "Imiquimod in the treatment of cutaneous warts: an evidence-based review," *American journal of clinical dermatology*, vol. 15, pp. 387-399, October 2014, doi: <https://doi.org/10.1007/s40257-014-0093-5>.
- [7] J. Zampella and B. Cohen, "Consideration of underlying immunodeficiency in refractory or recalcitrant warts: A review of the literature," *Skin Health and Disease*, vol. 2, no. 1, p. ski2. 98, March 2022, doi: <https://doi.org/10.1002/ski2.98>.
- [8] M. G. Hawkins *et al.*, "Detection of specific HPV subtypes responsible for the pathogenesis of condylomata acuminata," *Virology journal*, vol. 10, no. 137, pp. 1-9, May 2013, doi: <https://doi.org/10.1186/1743-422X-10-137>.
- [9] V. Gopal, M. M. Shenoy, and M. Pinto, "Common warts revisited: a clinical study," *International Journal of Research in Dermatology*, vol. 3, no. 2, Mar. 2017, doi: <https://doi.org/10.18203/issn.2455-4529.IntJResDermatol20172208>.
- [10] F. Dall'Oglio, V. D'Amico, M. R. Nasca, and G. Micali, "Treatment of cutaneous warts: an evidence-based review," *American journal of clinical dermatology*, vol. 13, pp. 73-96, April 2012, doi: <https://doi.org/10.2165/11594610-000000000-00000>.
- [11] D. Abeck, L. Tetsch, M. Lüftl, and T. Biedermann, "Extragenital cutaneous warts—clinical presentation, diagnosis and treatment," *JDDG: Journal der Deutschen Dermatologischen Gesellschaft*, vol. 17, no. 6, pp. 613-634, June 2019, doi: <https://doi.org/10.1111/ddg.13878>.
- [12] N. Redzic *et al.*, "Characterization of type-specific HPV prevalence in a population of persistent cutaneous warts in Flanders, Belgium," *Scientific reports*, vol. 13, no. 1, p. 17492, October 2023, doi: <https://doi.org/10.1038/s41598-023-44154-y>.
- [13] C. Olivera *et al.*, "Impact of high-risk and low-risk human papillomavirus infections on the male genital tract: effects on semen inflammation and sperm quality," *Frontiers in Cellular and Infection Microbiology*, vol. 14, Aug. 23, 2024, Art no. 1420307, doi: <https://doi.org/10.3389/fcimb.2024.1420307>.
- [14] Z. Ma *et al.*, "A comprehensive HPV-STI NGS assay for detection of 29 HPV types and 14 non-HPV sexually transmitted infections," *Infectious Agents and Cancer*, vol. 17, no. 1, p. 9, Mar. 2022, doi: <https://doi.org/10.1186/s13027-022-00420-8>.
- [15] A. Abate *et al.*, "Characterization of human papillomavirus genotypes and their coverage in vaccine delivered to Ethiopian women," *Scientific Reports*, vol. 14, no. 1, p. 7976, Apr 4 2024, doi: <https://www.nature.com/articles/s41598-024-57085-z>.

- [16] S. Yete, W. D'Souza, and D. Saranath, "High-Risk Human Papillomavirus in Oral Cancer: Clinical Implications," *Oncology*, vol. 94, no. 3, pp. 133-141, 2018, doi: <https://doi.org/10.1159/000485322>.
- [17] L. L. Zheng, S. F. Chen, F. Yang, W. H. Wang, C. Xu, and L. Y. Zheng, "High-risk HPV prevalence and genotype distribution among women in Liaocheng, Shandong Province, China from 2016 to 2022," *Front Public Health*, vol. 11, p. 1145396, March 2023, doi: <https://doi.org/10.3389/fpubh.2023.1145396>.
- [18] L. L. d. Silva *et al.*, "Malignancy associated with low-risk HPV6 and HPV11: a systematic review and implications for cancer prevention," *Cancers*, vol. 15, no. 16, p. 4068, Aug. 2023, doi: <https://doi.org/10.3390/cancers15164068>.
- [19] K. Yamada *et al.*, "Characteristics of anal canal squamous cell carcinoma as an HPV-associated cancer in Japan," *International Journal of Clinical Oncology*, vol. 28, no. 8, pp. 990-998, Aug. 2023, doi: <https://doi.org/10.1007/s10147-023-02339-5>.
- [20] T. F. Tsai *et al.*, "Estimating the burden of genital warts in Taiwan," *Sexual Health*, vol. 14, no. 6, pp. 485-491, Dec. 2017, doi: <https://doi.org/10.1071/SF17013>.
- [21] S. Akhavan, A. Mousavi, M. Modaresgilani, and A. Alibakhshi, "Genital warts (anogenital warts)," *Journal of Obstetrics, Gynecology and Cancer Research*, vol. 2, no. 1, 2022, doi: <https://doi.org/10.5812/ogcr.11440>.
- [22] J. Yuan *et al.*, "Genital warts treatment: Beyond imiquimod," *Human vaccines & immunotherapeutics*, vol. 14, no. 7, pp. 1815-1819, December 2018, doi: <https://doi.org/10.1093/cid/civ813>.
- [23] M. H. Muhammed and A. H. M. Sherwany, "The Prevalence and Clinical Features of Genital Warts among a sample of Patients in Erbil Governorate," *Advances in Medical Journal*, vol. 7, no. 2, pp. 30-35, Apr. 2022, doi: <https://doi.org/10.56056/amj.2022.175>.
- [24] P. A. Achdiat *et al.*, "A Review and Case Study of Genital and Extragenital Human Papillomavirus Type 6 and 11 Infections in Men Who Have Sex with Men Accompanied by Human Immunodeficiency Virus Infection," *HIV AIDS-Research and Palliative Care*, vol. 16, pp. 175-182, Mar. 2024, doi: <https://doi.org/10.2147/hiv.S451989>.
- [25] M. Daugherty and T. Byler, "Genital Wart and Human Papillomavirus Prevalence in Men in the United States From Penile Swabs: Results From National Health and Nutrition Examination Surveys," *Sexually Transmitted Diseases*, vol. 45, no. 6, pp. 412-416, Jun Jun 2018, doi: <https://doi.org/10.1097/OLQ.0000000000000761>.
- [26] A. Unal, "Analysis of HBsAg, Anti-HCV, Anti-HIV, VDRL, and TPHA test results in patients diagnosed with condyloma acuminata," *Annals of Medical Research*, vol. 30, no. 11, pp. 1428-1431, Nov. 2023, doi: <https://doi.org/10.5455/annalsmedres.2023.08.197>.
- [27] F. Erduran and A. Y. İyidal, "Evaluation of Serological Test Results of Other Sexually Transmitted Diseases in Patients with Anogenital Warts," *Journal of the Turkish Academy of Dermatology*, vol. 16, no. 3, pp. 58-61, 2022, doi: <https://doi.org/10.4274/jtad.galenos.2022.20592>.
- [28] E. Ünal *et al.*, "Serological test results of sexually transmitted diseases in patients with condyloma acuminata," *Advances in Dermatology and Allergology/Postepy Dermatologii i Alergologii*, vol. 32, no. 4, pp. 286-289, Aug 2015, doi: <https://doi.org/10.5114/pdia.2015.48065>.
- [29] M. Adeli, L. Moghaddam-Banaem, and S. Shahali, "Sexual dysfunction in women with genital warts: a systematic review," *BMC Women's Health*, vol. 22, no. 1, p. 516, December 2022, doi: <https://doi.org/10.1186/s12905-022-02073-6>.
- [30] M. S. Samaan and M. A. Gaber, "Effect of multiple genital and extragenital warts on quality of social life," *Menoufia Medical Journal*, vol. 34, no. 3, pp. 920-925, October 2021, doi: https://doi.org/10.4103/mmj.mmj_96_20.
- [31] M. A. Shareef *et al.*, "Characteristics of Patients with Anogenital Wart: An Observational and Comparative Study," *Bahrain Medical Bulletin*, vol. 43, no. 3, Sep. 2021. Available online at: https://www.bahrainmedicalbulletin.com/SEPT_2021/BMB-21-75.pdf.
- [32] M. Gönül *et al.*, "Mucocutaneous warts in Middle Anatolia, Turkey: clinical presentations and therapeutic approaches," *Advances in Dermatology and Allergology/Postepy Dermatologii i Alergologii*, vol. 32, no. 3, pp. 179-183, June 2015, doi: <https://doi.org/10.5114/pdia.2015.48054>.
- [33] S.-Z. Qi *et al.*, "Human papillomavirus-related psychosocial impact of patients with genital warts in China: a hospital-based cross-sectional study," *BMC Public Health*, vol. 14, pp. 1-8, Jul 21 2014, doi: <https://doi.org/10.1186/1471-2458-14-739>.
- [34] N. Asghar, M. Asghar, N. Rehman, I. U. Afridi, and S. Khalid, "Epidemiological and clinical patterns of viral warts presenting to dermatology OPD of Hayatabad Medical Complex, Peshawar: Epidemiological and clinical patterns of viral warts," *Journal of Pakistan Association of Dermatologists*, vol. 32, no. 1, pp. 78-84, 2022: January-March. Available online at: <https://www.jpap.com.pk/index.php/jpad/article/view/1856>.
- [35] T. A. Tiiti, S. G. Selabe, J. Bogers, and R. L. Lebelo, "High prevalence of and factors associated with human papillomavirus infection among women attending a tertiary hospital in Gauteng Province, South Africa," *BMC cancer*, vol. 22, no. 1, p. 854, Aug 2022, doi: <https://doi.org/10.1186/s12885-022-09964-9>.
- [36] T. Abd-ElRaheem, S. El-Tahlawy, N. El Sherbiny, M. Nassar, and S. Boureikaa, "Prevalence and risk factors associated with cutaneous warts in Fayoum primary school children," *Fayoum University Medical Journal*, vol. 3, no. 1, pp. 24-28, June 2019, doi: <https://doi.org/10.21608/fumj.2019.60378>.
- [37] G. M. Magalhães, É. C. Vieira, L. C. Garcia, M. d. L. R. De Carvalho-Leite, A. C. M. Guedes, and M. G. Araújo, "Update on human papilloma virus-part I: epidemiology, pathogenesis, and clinical spectrum," *Anais Brasileiros de Dermatologia*, vol. 96, no. 1, pp. 1-16, 2021 Jan.-Feb, doi: <https://doi.org/10.1016/j.abd.2020.11.003>.
- [38] A. Hadi, Y. Al-Mawlah, W. Al-Janabi, and L. Majeed, "Human Papillomavirus: It's Characteristics, Pathogenesis, Transmission, Immunity, and it's Role in Cervical Cancer: A Mini Review," *Journal of Water Res*, vol. 1, no. 1, pp. 65-72, Mar. 2023, doi: <https://dx.doi.org/10.33140/JWR>.
- [39] N. Essa, M. A. Saleh, R. M. Mostafa, E. A. Taha, and T. A. Ismail, "Prevalence and factors associated with warts in primary school children in Tema District, Sohag Governorate, Egypt," *Journal of the Egyptian Public Health Association*, vol. 94, pp. 1-6, Jan. 2019, doi: <https://doi.org/10.1186/s42506-018-0007-0>.
- [40] S. Karki, M. Pradhan, and A. Rai, "Warts among patients visiting the outpatient department of dermatology in a tertiary care centre: a descriptive cross-sectional study," *Journal of the Nepal Medical Association*, vol. 60, no. 253, pp. 770-3, 2022, doi: <https://doi.org/10.31729/jnma.7544>.

- [41] N. Al-Mutairi and M. AlKhalaf, "Mucocutaneous warts in children: clinical presentations, risk factors, and response to treatment," (in eng), *Acta Dermatovenerologica Alpina, Pannonica et Adriatica*, vol. 21, no. 4, pp. 69-72, Dec. 2012. Available online at: <https://pubmed.ncbi.nlm.nih.gov/23599126/>.
- [42] Y. Jayasinghe and S. M. Garland, "Genital warts in children: what do they mean?," *Archives of disease in childhood*, vol. 91, no. 8, pp. 696-700, Aug 2006, doi: <https://doi.org/10.1136/adc.2005.092080>.
- [43] J. B. Karnes and R. P. Usatine, "Management of external genital warts," *American family physician*, vol. 90, no. 5, pp. 312-318, Sep. 1, 2014. Available online at: <https://www.aafp.org/pubs/afp/issues/2014/0901/p312.pdf>.
- [44] G. Tchernev, "Sexually transmitted papillomavirus infections: epidemiology pathogenesis, clinic, morphology, important differential diagnostic aspects, current diagnostic and treatment options," *Anais brasileiros de dermatologia*, vol. 84, pp. 377-389, Jul-Aug 2009, doi: <https://doi.org/10.1590/s0365-05962009000400009>.
- [45] A. Grosu-Bularda *et al.*, "Clinicopathological Findings and Comprehensive Review of Buschke–Lowenstein Tumors Based on a Case Study," *Journal of Personalized Medicine*, vol. 14, no. 8, p. 887, August 2024, doi: <https://doi.org/10.3390/jpm14080887>.
- [46] V. R. Yanofsky, R. V. Patel, and G. Goldenberg, "Genital warts: a comprehensive review," *The Journal of clinical and aesthetic dermatology*, vol. 5, no. 6, p. 25, Jun. 2012. Available online at: <https://pubmed.ncbi.nlm.nih.gov/22768354/>.
- [47] K. Na, J. Y. Sung, and H.-S. Kim, "Clinicopathological characteristics of high-grade squamous intraepithelial lesions involving condyloma acuminatum," *Anticancer Research*, vol. 38, no. 3, pp. 1767-1774, March 2018, doi: <https://doi.org/10.21873/anticancer.12414>.
- [48] C. Y. Cho, Y. C. Lo, M. C. Hung, C.-C. Lai, C. J. Chen, and K. G. Wu, "Risk of cancer in patients with genital warts: A nationwide, population-based cohort study in Taiwan," *PLoS One*, vol. 12, no. 8, Aug. 2017, doi: <https://doi.org/10.1371/journal.pone.0183183>.